



**PATIENT PRESENTING CLINICAL SIGNS**

Stewie Popsecu

History: Mildly elevated ProBNP. Grade 1/6 murmur. Clinically normal. Assess prior to anesthesia.

**SPECIES ECHOCARDIOGRAM FINDINGS**

Feline

2D, m-mode, color flow and doppler imaging is available. The left ventricular wall is mildly remodeled with a focal septal thickening. The remainder of the LV wall measures normal. There is a mildly hyperechoic endocardium consistent with fibrosis. The papillary muscles are mildly remodeled and hyperechoic. The left atrium is normal in size. The right atrium is normal in size. The right ventricle appears normal. The mitral valve is normal in structure and mobility. No MR. Trace TR. Blood flow through the RVOT and LVOT is normal in velocity. No pleural or pericardial effusion seen. No obvious cardiac tumors.

BREED

DSH

**CARDIAC CHART**

SEX

Male Neutered

AGE

14 years

WEIGHT

18.3lbs

INTERPRETED BY

Maggie Machen  
Lamy, DVM, DACVIM  
(Cardiology)

IMAGING PERFORMED BY

Rebekah Jakum, CVT  
ARDMS/RVT

HOSPITAL NAME

Lehigh Valley AH  
(Bath)

REFERRING VET

Dr. Tan

INVOICE

29191

DATE

2/22/23

FELINE CARDIAC PARAMETERS	BODY WEIGHT (kg)	HR (BP M)	IVSd (cm) (Moise, Pipers)	LVIDd (cm) (Moise, Pipers)	LVWd (cm) (Moise, Pipers)	FS (%)	EF (%)
NORMAL PARAMETER	-----	150 - 240	3.5-0.55	<2 (mean 1.5)	3.5-0.55	35-67	80-100
PATIENT	8.3	175	0.63	1.4	0.47	66	95
FELINE CARDIAC PARAMETERS	LA/AO (Boon)	LA/AO HEART BASE (Swe) (Abbott)	LA 2D short axis Base view (cm) (Abbott)	LVOT VEL (m/s)	RVOT VEL (m/s)	E max (m/s)	
NORMAL	<1.5	<1.3	<1.2	<1.6	<1.3	<0.9	
PATIENT	NM	1.3	1.2	1.0	0.9	N	

*\*Note: All measurements based upon multi-modal images and methods. An average value is reported.  
Adapted from June Boon, Veterinary Echocardiography, 1998  
Abbott J & MacLean H JVIM 2006;20: 111-119, Moise et al. Am J Vet Res 47:1476, 1986. Pipers et al. Am J Vet Res 40:882, 1979.*

**INTERPRETATION OF THE FINDINGS & FURTHER RECOMMENDATIONS**

Mild focal LV hypertrophy is present in addition to mild LV remodeling, which may be indicative of early hypertrophic disease or may simply represent a normal variant. Regardless, the LA remains normal which would indicate clinical stability. Serial echocardiography will be necessary to determine progression and clinical significance. Additionally, no definitive cause is identified for the murmur in this study, making it likely benign and secondary to tachycardia/stress. Monitor BP/T4 every 6-12 months.

With a normal LA dimension, no medications are indicated. Prognosis is open pending assessing for progression.

Given these findings, anesthetic risk is mild, however any cat with this degree of fibrosis and diastolic dysfunction will be at risk for iatrogenic IV fluid overload should they be needed in the future. Monitor for any development of clinical signs, including labored breathing or signs of a blood clot (paralysis, neurologic change).

A recheck echocardiogram is recommended in 6-12 months to screen for any evidence of progression.

**IMAGES**



**PATIENT**

Stewie Popsecu

**SPECIES**

Feline

**BREED**

DSH

**SEX**

Male Neutered

**AGE**

14 years

**WEIGHT**

18.3lbs

**INTERPRETED BY**

Maggie Machen  
Lamy, DVM, DACVIM  
(Cardiology)

**IMAGING  
PERFORMED BY**

Rebekah Jakum, CVT  
ARDMS/RVT

**HOSPITAL NAME**

Lehigh Valley AH  
(Bath)

**REFERRING VET**

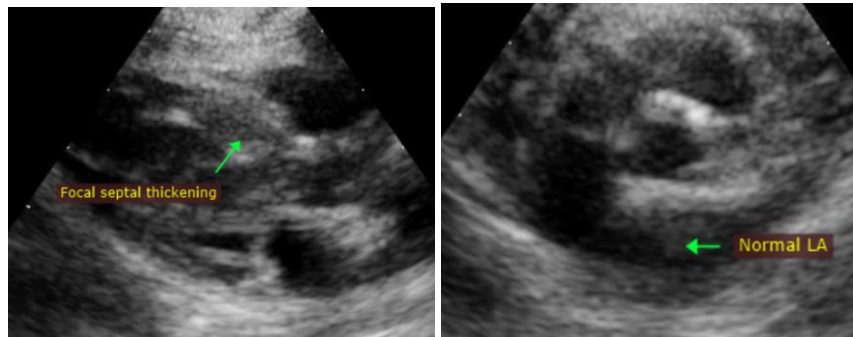
Dr. Tan

**INVOICE**

29191

**DATE**

2/22/23



The information and recommendations provided are based on the images presented by the referring veterinarian. No evaluation can be communicated regarding pathology that was not visible in the image/video clips provided.

Thank you for this referral. If the clinical or image interpretation does not parallel your findings or if I can be of any further assistance please contact me.

**Maggie Machen Lamy, DVM**  
Diplomate of the American College of Veterinary Internal Medicine (Cardiology)  
info@sonopath.com